

See discussions, stats, and author profiles for this publication at: <https://www.researchgate.net/publication/357322908>

# Foramen magnum meningioma: Surgical planning Analysis with 3d printing

Article · June 2021

DOI: 10.47755/2766-9661.1000106

CITATION

1

READS

18

8 authors, including:



**Castillo-Rangel Carlos**

Universidad Nacional Autónoma de México

33 PUBLICATIONS 49 CITATIONS

[SEE PROFILE](#)



**Ordoñez Granja Jaime**

Instituto de Seguridad y Servicios Sociales de los Trabajadores del Estado

7 PUBLICATIONS 3 CITATIONS

[SEE PROFILE](#)



**Gerardo Marín**

Universidad Veracruzana

17 PUBLICATIONS 3 CITATIONS

[SEE PROFILE](#)

Some of the authors of this publication are also working on these related projects:



Deep Brain Stimulation [View project](#)



Intelligence and consciousness [View project](#)

## Foramen magnum meningioma: Surgical planning Analysis with 3d printing

Carlos Castillo Rangel<sup>1</sup>, Jonathan S Zúñiga Córdova<sup>2\*</sup>, Arturo Rojo Noriega<sup>2</sup>, Juan M Morales Sánchez<sup>2</sup>, Alberto A Mejía Frías<sup>2</sup>, Rafael Avendaño Pradel<sup>3</sup>, Jaime Ordoñez Granja<sup>3</sup>, Gerardo Marín Márquez<sup>4</sup>

<sup>1</sup>Neurosurgery Chairman, Hospital Regional 1° de Octubre, Institute of Social Security and Services for State Workers (ISSSTE), Mexico

<sup>2</sup>Resident in neurosurgery specialization, Hospital Regional 1° de Octubre, Institute of Security and Social Services for State Workers ("ISSSTE"), Mexico

<sup>3</sup>Doctor assigned to the neurosurgery service, "Hospital Regional 1° de Octubre", Institute of Social Security and Services for State Workers (ISSSTE), Mexico

<sup>4</sup>Brain Research Institute, Xalapa, Veracruz, Mexico

\***Correspondence to:** Jonathan S Zúñiga Córdova, Resident in neurosurgery specialization, Hospital Regional 1° de Octubre, Institute of Security and Social Services for State Workers ("ISSSTE"), Mexico, E-mail: jzuniga699@gmail.com

**Received:** 13 May 2021; **Accepted:** 03 June 2021; **Published:** 10 June 2021

**Copyright:** © 2021 Zúñiga Córdova JS, et al. This is an open-access article distributed under the terms of the Creative Commons Attribution License, which permits unrestricted use, distribution, and reproduction in any medium, provided the original author and source are credited.

### Abstract

**Introduction:** Foramen magnum meningiomas corresponds about 3 to 3.2% of all meningiomas. And 60 to 77% of all benign extramedullary tumors of the craniocervical junction. Due to its depth, these lesions and the delicate anatomical relationships, their resection demands detailed mastery and control of the complex anatomy of the region. Different approaches for resection of these lesions have been reported: suboccipital, transcondylar, transoral and retrosigmoid craniotomy.

Far lateral transcondylar approach have proved to be a safe, wide, sterile surgical access for the exposition of the ventral space to the central nervous system that allows good manipulation in a parallel plane. There are specific considerations according to the position and encasement of the vertebral artery, and the extension of the bone resection.

With the development of three-dimensional (3D) printing technology, more applications have been used in clinical settings for the planning and performance of surgical procedures, and neurosurgery is not the exception. 3D printed models are created through layer-by-layer deposition by high-precision 3D printers using reconstructed patient CT-scan images.

**Materials and methods:** The clinical case of a patient with a diagnosis of foramen magnum meningioma, pre-surgical planning with a 3D model, surgical resolution, and literature review are presented.

**Results:** Pre-surgical planning is performed on a 3D model, the patient undergoes surgical resolution without complications and she is discharged from the service due to improvement.

**Conclusion:** The use of current tools allows adequate and precise planning of neurosurgery procedures, as well as extensive explanation and taking individual anatomical considerations to reduce the risk of complications during surgery. 3D models represent a valuable surgical educational tool that improves the understanding of complex lesions of the skull base, for the neurosurgical residents.

**Keywords:** Meningioma; Foramen magnum; 3D printing; Far lateral, Transcondylar.

### Introduction

The foramen magnum (FM) is an anatomical region located near the medulla oblongata, in the lower half of the brainstem; it is worth noting that the lower cranial nerves and the vertebral arteries lie within this region.

Foramen magnum meningiomas corresponds about 3 to 3.2% of all meningiomas. And 60 to 77% of all benign extramedullary tumors of the craniocervical junction. These tumors are classified according to its localization in ventral or dorsal, according to a coronal plane located between the first dentate ligament and then in the cranial nerve, and the cephalocaudal

extension from the inferior third of the clivus to the axis. Due to its depth, these lesions and the delicate anatomical relationships, their resection demands detailed mastery and control of the complex anatomy of the region. Different approaches for resection of these lesions have been reported: suboccipital, transcondylar, transoral, endonasal endoscopic, stereotactic radiosurgery and retro-sigmoid craniotomy. The far lateral retrocondylar (FLR) is one of the most delicate neurosurgical interventions that are employed to remove these tumors [1-3].

Localization of the dural tail, is particularly important in these cases, when the dural tail is attached to the inferior third of the clivus and the meningioma extends caudally, this variety is classified as clivo-spinal, but when dural tail is attached to the upper portion of the spinal canal with rostral extension, this lesion is classified as spinoclivar. This differentiation is important because of the spinoclivar variety offers a better arachnoid dissection plane between the tumor and the adjacent anatomical structures, than the clivo-spinal variety [4].

In recent years, the emergence of 3D printed cranial skull models has provided promising conditions for surgery simulations, which are useful for preoperative design, accumulating experience and validating results and which could effectively improve surgical results and decrease surgical complications. In addition to surgical planning, a great advantage of these models is the adequate visualization of highly complex structures and lesions, this allows an improvement in the doctor-patient relationship, allowing for a detailed explanation of the procedure, complications, gauging the complexity of the surgery [5].

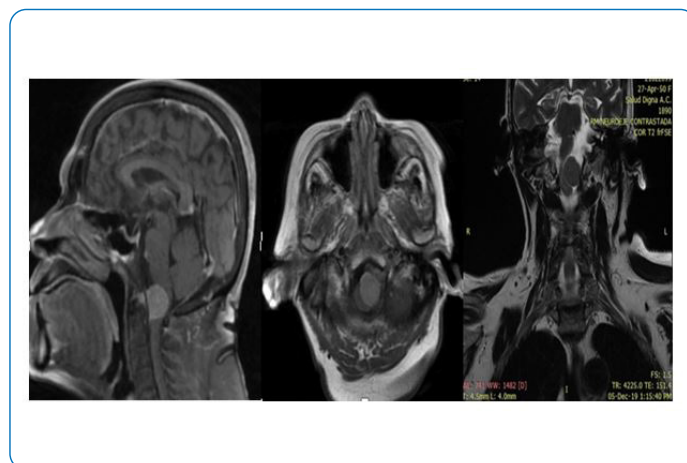
## Materials and methods

We present a clinical case of a 69-year-old female with a history of systemic arterial hypertension with 3 years of progression, gonarthrosis with 1 year of progression. The current suffering began about 1 year ago with a 10/10 burning pain intensity of the pelvic limbs, which makes walking difficult, relieved with analgesics and rest; 6 months ago she began having a progressive and disabling decrease in upper limb strength, which is why she was sent to this unit for study.

She admitted with a Glasgow score of 15 points, preserved higher mental functions, alertness, decreased swallowing reflex, hypotrophy and deviation of the tongue towards the left, with upper extremity strength of 4/5 +++/++++ Hoffman and Trommer (+), lower extremity strength of 4/5 +++/++++, Babinski reflex was not evoked, hypoesthesia in dermatome C5 to T12, vibration and preserved batiesthesia.

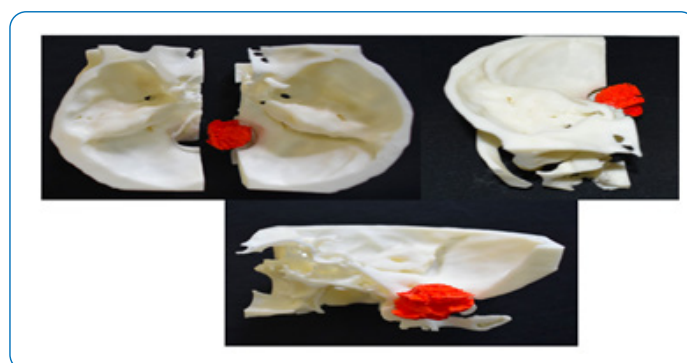
An MRI of the brain was performed in axial, sagittal and coronal slices in T1 contrasted with gadolinium in which a hyperintense lesion with homogeneous enhancement was observed at the level of the foramen magnum, thus the pre-surgical protocol was carried out and the decision was made to perform resection of the lesion

(Image 1).



**Image 1:** Three-dimensional biomodels improve doctor-patient communication, improve surgeon's skill, while helping us to individualize cases.

The Neurosurgery Service at the "Hospital Regional 1° de Octubre" carried out the pre-surgical protocol, the model was processed in the research center and the biomechanical laboratory "CILAB", reconstruction was done with the MIMICS system, in a ZORTRAX 300 printer. In Z-ULTRAT material, from the DICOM file (Image 2).

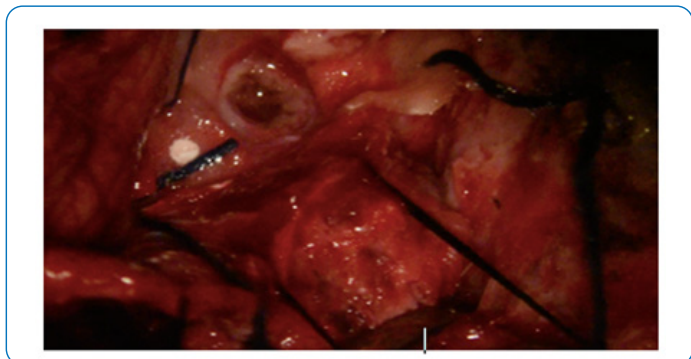

**Image 2:** 3D printing in axial and sagittal section showing detailed anatomical structures at the bone level of the skull base with focus on the foramen magnum, as well as projection and tumor location (red color), interaction with the model allows planning of the approach and bone corridors for lesion resection without affecting adjacent structures.

## Technique:

Surgery is performed in two stages: 1st stage, the patient is in park bench position, an extreme lateral approach is performed, dissecting through muscular planes, locating the suboccipital triangle to locate V3, subsequently, location of the posterior arch of C1 and transverse process of C1 and C2, the foramen magnum is located, trepanation is made 1cm from the lower occipital line. A minicraniectomy is performed with a lateral cut aided by Midas Rex drill, preserving dura matter integrity; the 2nd surgical stage includes SSEP and MEP monitoring, with removal of the C1 arch, during microsurgical arachnoiditis is observed, which is dissected,

a solid tumor lesion is located with mass effect on the brainstem, debulking is performed, luxation of the lesion is performed, with adequate visualization of cranial nerves XI and XII at the end of the basilar artery with 90% tumor extraction (Image 3).



**Image 3:** Trans-surgical image showing in situ tumor location in foramen magnum, homogeneous in appearance, solid consistency and compression of adjacent structures.

## Discussion

Application of 3D technology in conjunction with neurosurgery has seen a great rise, and lately application of this technology has been reported in the study of anatomy, tumors, cerebrovascular diseases and functional diseases. Due to the complex structure of the skull base, the tumor is closely connected to nervous and vascular structures; as a result, the risk of surgery is high, the total resection rate is low, and postoperative complications are high. Due to these reasons, the use of 3D printed models represents the correct anatomical position, allowing for the possibility of choosing the most appropriate surgical approach in each case [6].

The occipital bone is made up of the foramen magnum, the occipital condyles in an anterolateral situation and the hypoglossal canals anterior to the condyles; morphological and morphometric variations in the occiput may coexist in the same individual, likewise, variations in pathological processes (tumors, aneurysms, congenital or acquired malformations and trauma) may occur, so the different surgical approaches require great mastery of the surgical procedure techniques and a deep understanding of anatomy [7].

Foramen magnum meningiomas account for approximately 0.3 to 3.2% of the total incidence of meningiomas; however, they are usually benign extra-axial intracranial tumors close to the craniocervical junction. Handling them is usually challenging in view of the limited space between the cervicomedullary junction and the clivus in the foramen magnum, as well as the compromise between the brainstem, spinal cord, lower cranial nerves, and vertebral artery [8].

These lesions have a slow growth rate and allow patients to remain asymptomatic for a long time, so these tumors are diagnosed at an advanced stage; surgical treatment presents complications such as occipitocervical instability, prolonged duration of the procedure, high incidence of pain at the surgical site and the possibility of injury to the vertebral artery or the XII cranial nerve, representing an additional challenge during surgery [8].

In 1988, George et al. described the extreme lateral approach for these tumors, however, multiple modifications of this approach have been described so far with a lower risk of complications; variations include resection of the occipital condyle, resection of the superior facet of C1, resection of the jugular tubercle, mastoidectomy, and dissection of the hypoglossal canal. In recommendations published to date, it is suggested that the craniocervical junction should be stabilized with fusion when more than 70% of the occipital condyle is removed [9-11].

## Conclusion

Surgery simulation in 3D models reduces the risk of injury to vital structures, decreases the rate of complications, helping the surgeon's motor memory and spatial vision at the time of surgery, as well as allowing adequate surgical planning.

The development of new technologies such as 3D model printing for surgical planning is kept in constant development and innovation in first world hospitals.

Three-dimensional biomodels improve doctor-patient communication, improve surgeon's skill, while helping us to individualize cases.

## Declarations

### Ethics approval and consent to participate:

Not applicable

### Consent for publication:

Written informed consent was obtained from the patient for publication of this case report.

### Availability of data and material:

Not applicable

### Competing interests:

The authors declare that they have no competing interests

## References

1. Leon-Ariza DS, Campero A, Romero Chaparro R, Prada DG, Vargas Grau GV, et al. "Key Aspects in Foramen Magnum Meningiomas: From Old Neuroanatomical Conceptions to Current Far Lateral Neurosurgical Intervention". *World Neurosurgery* 106(2017): 477-483.
2. Arnautovic KI, Al-Mefty O, Husain M. „Ventral foramen magnum meningiomas“. *J Neurosurg* 92 (2000): 71-80.
3. Flores BC, Boudreaux BP, Klinger DR, Mickey BE and Barnett SL. „The far-lateral approach for foramen magnum meningiomas“. *Neurosurgical Focus* 35(2013).
4. Bernard F, Lemee JM, Delion M, Fournier HD. „Lower third clivus and foramen magnum intradural tumor removal: The plea for a simple posterolateral approach“. *Neurochirurgie* 62(2016): 86-93.

5. Lan Q, Zhu Q, Xu L, Xu T. „Application of 3D-Printed Craniocerebral Model in Simulated Surgery for Complex Intracranial Lesions“. *World Neurosurgery* 134(2020): 761-770.
6. Xiao-Yu Guo, Zhen-Qiang He, Hao Duan, Fu-Hua Lin, Guan-Hua Zhang et al. „The utility of 3-dimensional printed models for skull base meningioma surgery.“ *Ann Trans Med* 8(2020): 370.
7. Lyrtzis Ch, Gkioka, Anastasopoulos, Apostolidis, Natsis. „Foramen magnum, occipital condyles and hypoglossal cannals morphometry: anatomical study with clinical implications“. *Folia Morphol* 76(2017): 446-457.
8. Srinivas, Sarma, Deora , Beniwal , Vikas , Rao , et al. ”Tailored” far lateral approach to anterior foramen magnum meningiomas - The importance of condylar preservation“. *Neurol Ind* 67(2019): 142-148
9. Schaller Karl. „Foramen Magnum Tumors: Posterior Approaches and outcome“. *Surg Cranio-vertebral Junction* (2020): 403-412.
10. Bruneau M, George B. “Foramen magnum meningiomas: detailed surgical approaches and technical aspects at Lariboisière Hospital and review of the literature”. *Neurosurg rev* 31(2008):19-33.
11. Gargiulo P, Árnadóttir I, Gíslason M, Edmunds K, Ólafsson I. “New directions in 3D medical modeling: 3D-printing anatomy and functions in neurosurgical planning”. *J Healthc Eng* (2017):1-8.

**Citation:** Rangel CC, Cordova J S Z , Noriega AR, Sanchez JMM, Mejia Frias A A “Foramen magnum meningioma: Surgical planning Analysis with 3d printing”*J Neuro Brain Res* (2021): doi: 10.47755/2766-9661.1000106